



Bitte scrollen!

Die linksseitigen permanenten Mittelgesichtsschmerzen und Beschwerden äussern sich wie folgt:

Auf dem nachfolgenden Foto zeichnete ich den Hauptschmerz ein. Die permanenten Schmerzen sind beim Augenwinkel (Hauptschmerz) am stärksten. Von da aus (Hauptschmerz) gehen die Schmerzen über Wange, Auge, Ohr und obere hintere Zähne. Je stärker die permanenten Schmerzen in dieser eingezeichneten Region (Hauptschmerz) sind, desto mehr verstärken sich auch die Schmerzen Wange, Auge, Ohr und obere hintere Zähne. Manchmal strahlen die Schmerzen über den Hinterkopf bis in den Daumen der linken Hand aus. Der Ausgangspunkt ist aber immer beim eingezeichneten Hauptschmerz.

Vor der ersten OP im Mai 2007 hatte ich Schmerzen unterhalb des Auges (Wange) bis zum Ohr. Und eine leichte Schwellung unterhalb des Auges. Nach dieser OP im Mai 2007 verstärkten sich die Schmerzen mit dem ersten Migränenschub nach der OP enorm. Der Arzt meinte, dass es sich um den Trigeminusnerv handelt, der solche Schmerzen verursacht.

Es sind stechende, brennende, pulsierende und drückende Mittelgesichtsschmerzen links, ausgehend vom Augenwinkel (Hauptschmerz) über Wange, Auge und Ohr. Manchmal auch ein elektrisieren der oberen hinteren Zähne. Die Schmerzen verstärken sich zum Beispiel bei Wetterwechsel (Föhn, Bise). Aber auch kalte und trockene Luft sowie ätherische Öle und Nasensprays verstärken die Schmerzen. Bis vor die dritte Operation hat auch Migräne die Schmerzen verstärkt. Seit dieser Operation kann ich die Migräne von den Gesichtsschmerzen fast nicht mehr unterscheiden. Wenn die Schmerzen sehr stark sind, wird auch das linke Ohr rot und manchmal, fängt auch das linke Auge an zu tränen. Auch habe ich seit 2007 eine leichte Schwellung unterhalb des linken Auges.

Hinzu kommen seit 2007 ständiger linksseitiger Schleimfluss in Rachen, eitrige linksseitige Ausgüsse, häufiges Niesen und Husten sowie ein linksseitiger übler Geruch. Und seit Mitte 2012 geschwollener Lymphknoten. Sowie seit Anfang 2013 einseitig geschwollene Schilddrüse.



Please scroll!

The left-sided permanent mid-facial pain and complaints manifest as follow:

On the enclosed photo I have marked the main pain. From there, the pain goes to the cheek, eye, ear and upper back teeth. The more strong the pain in this region is I have marked (main pain) the more increase the pain in cheek, eye, ear and upper back teeth.

Before the first surgery in May 2007, I have had pain below the eye (cheek) until to the ear and a slight swelling below the eye. After this surgery in May 2007 the pain increased dramatically with the first migraine push after the surgery. The doctor said that this is the trigeminal nerve that causes such pain. Starting from the inner corner of my eye (marked as the main pain) about the cheek, eye, ear. The constant strongest pain is always on the corner of the eye (marked main pain). The more the pain is in this region (main pain), the more stronger is the pain in the eye, cheek, ear and upper back teeth. Sometimes the pain radiates to the back of the head and until to the left thumb. As I have said the starting point is always as I have marked as main pain.

There are stinging, burning, pulsating and pressing pain on the left midfacial. Starting from the corner of the eye (main pain) about the cheek, the eye until to the ear. Sometimes a electrify the upper back teeth. The pains increase, for example, when the weather changes

(foen, bise). But also cold and dry air as well as essential oils and nasal sprays increase the pain. Until the third surgery in 2009 has also increased migraine the pain. Since that surgery, I can distinguish migraine from facial pain any more. If the pain is very strong, even the left ear is red and sometimes the left eye starts to tear. I have also since 2007 a slight swelling below the left eye.

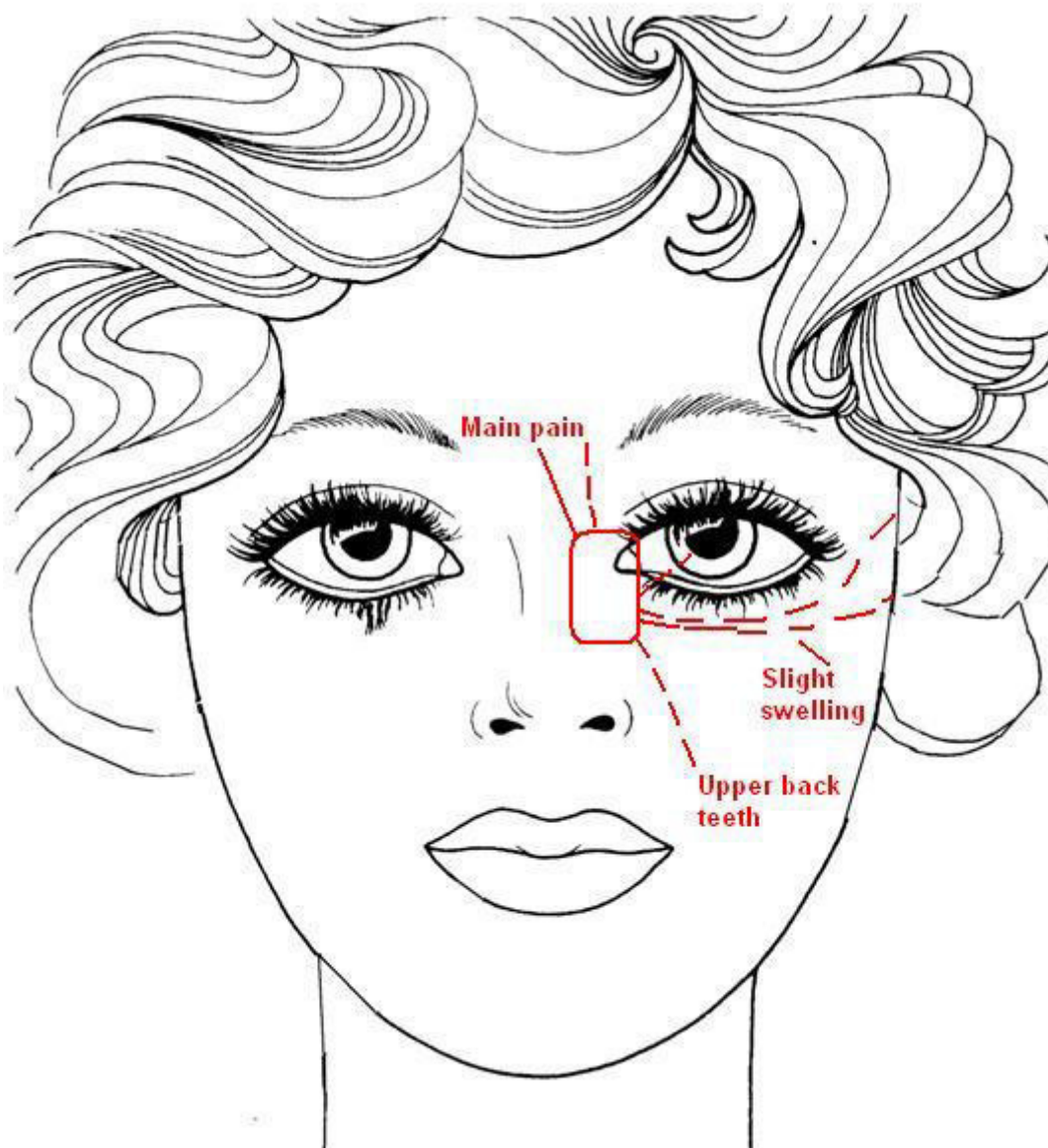
In addition since 2007 a constant flow of mucus in the throat left-sided, sometimes a pussy discharge coming out from my left nose, frequent sneezing and coughing and a unpleasant odor also left-sided.

And since mid-2012, swollen lymph nodes. As well as since the beginning of 2013 unilaterally swollen thyroid.

2007 Surgery a doctor removed the cyst.

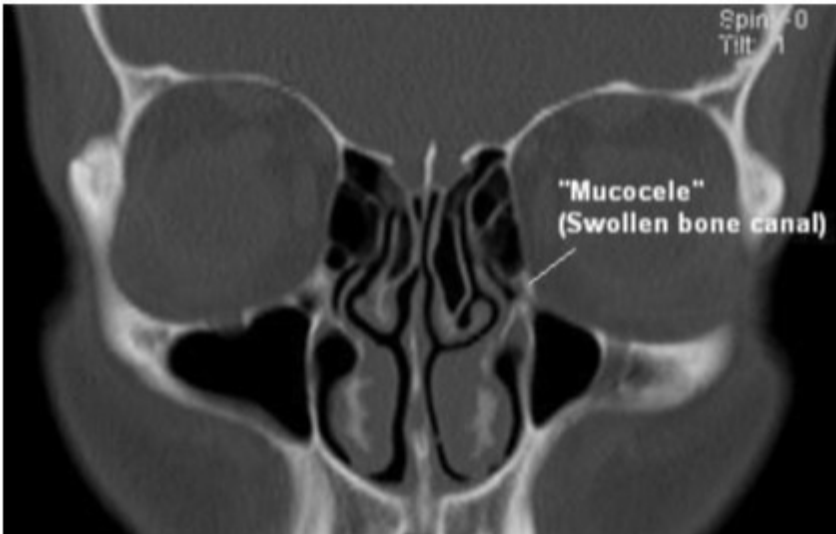2008 Surgery a doctor removed the cyst

2009 Surgery a doctor treated a chronical sinusitis (Sinus maxillary)

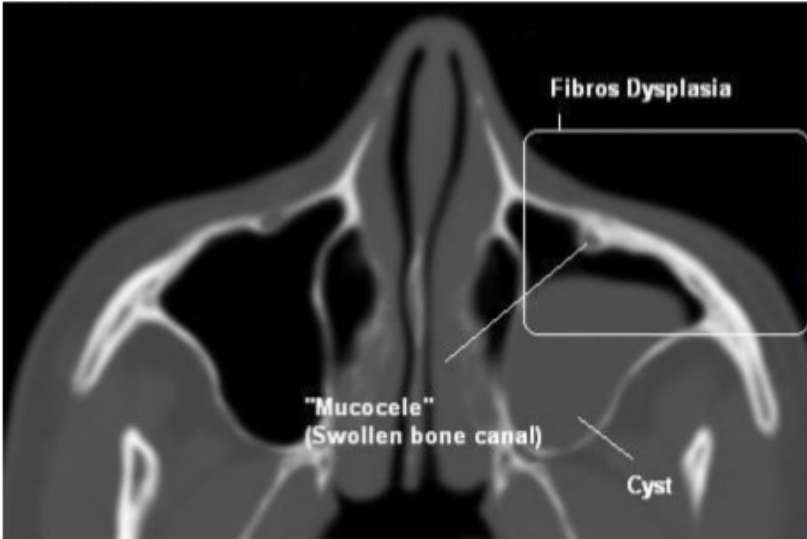


2007 Before the first surgery

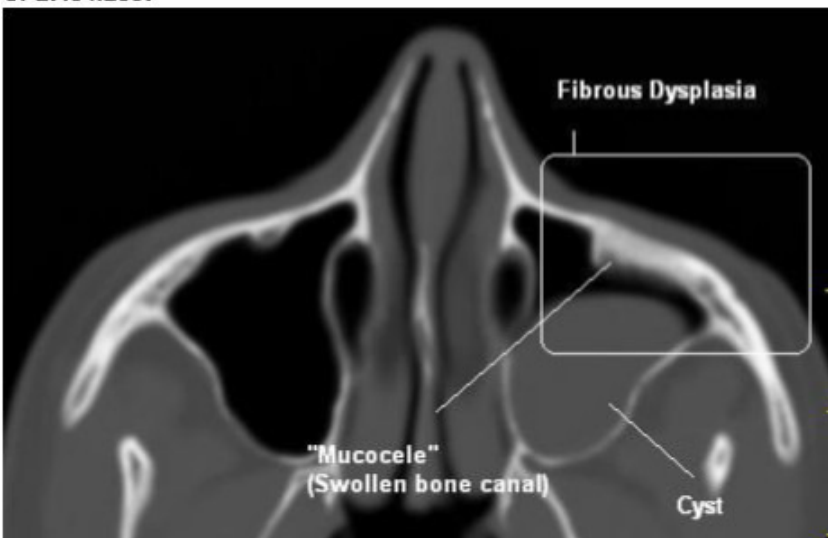
CT 27.04.2007



CT 27.04.2007

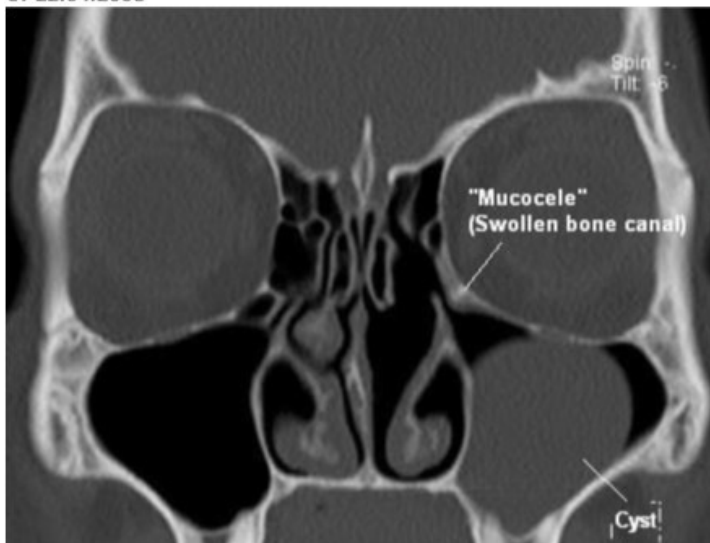


CT 27.04.2007

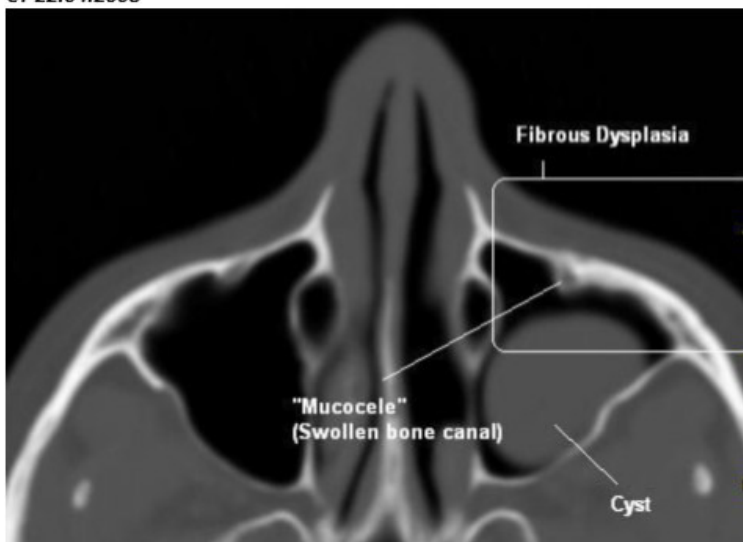


Before the second surgery

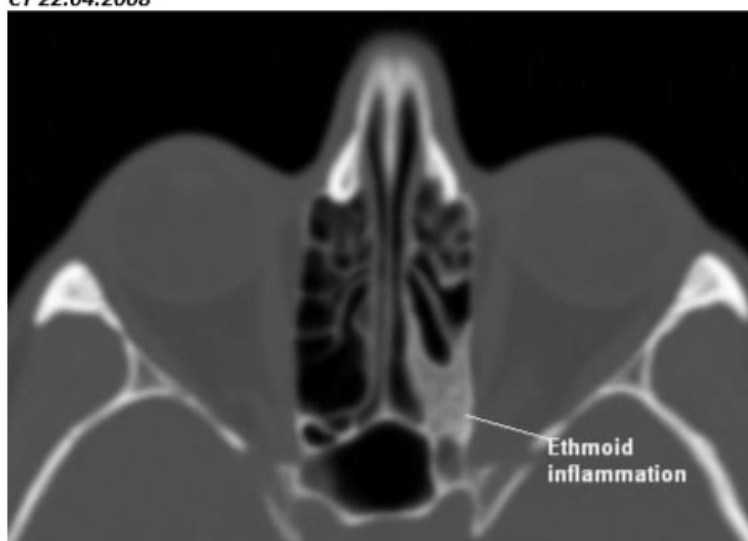
CT 22.04.2008



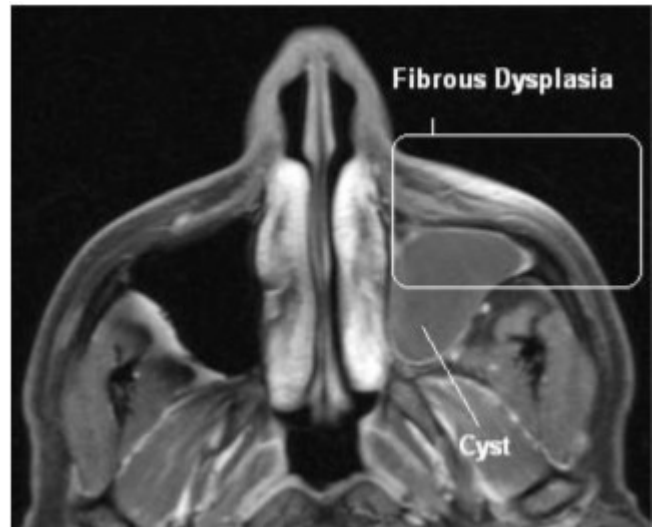
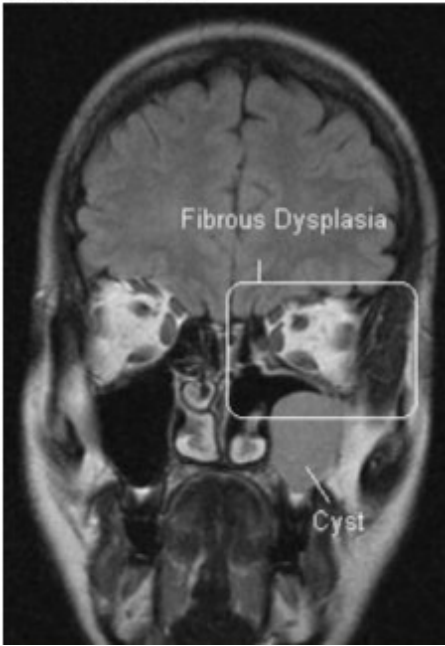
CT 22.04.2008



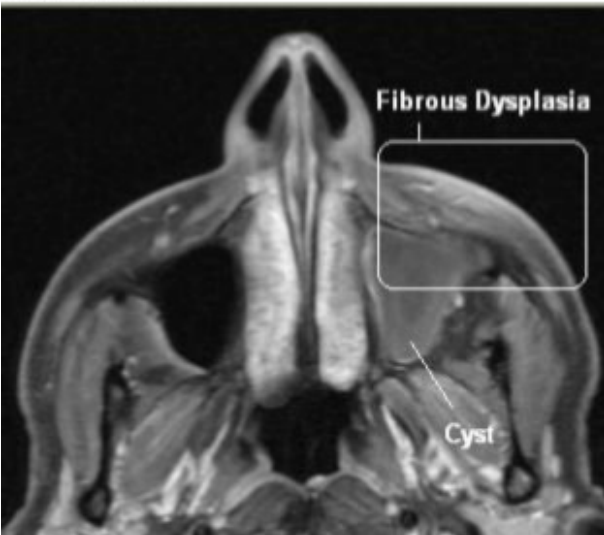
CT 22.04.2008



MRI 15.05.2008

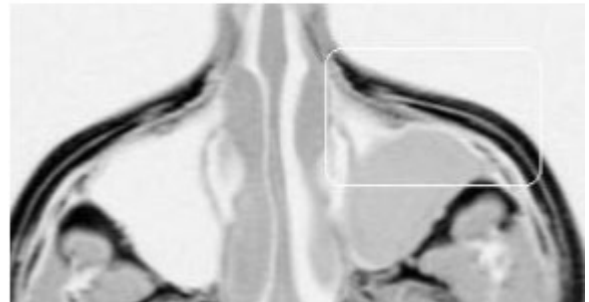


MRI 15.05.2008

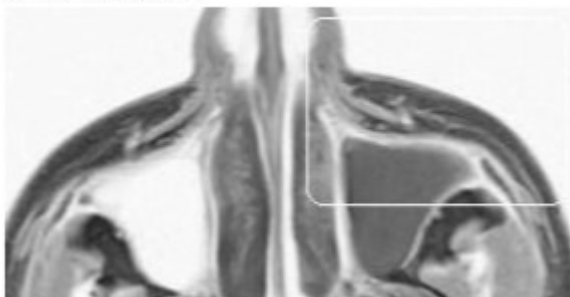


(Pinched trigeminal nerve)

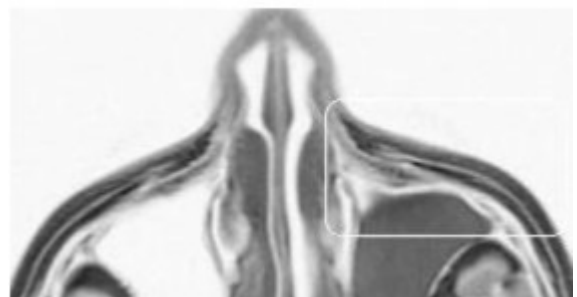
MRI 15.05.2008



MRI 15.05.2008

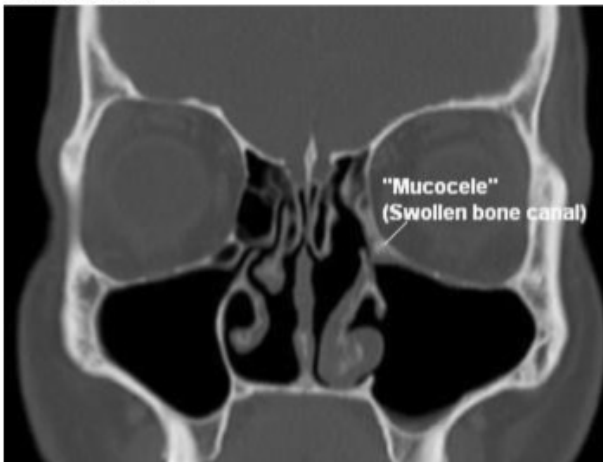


MRI 15.05.2008

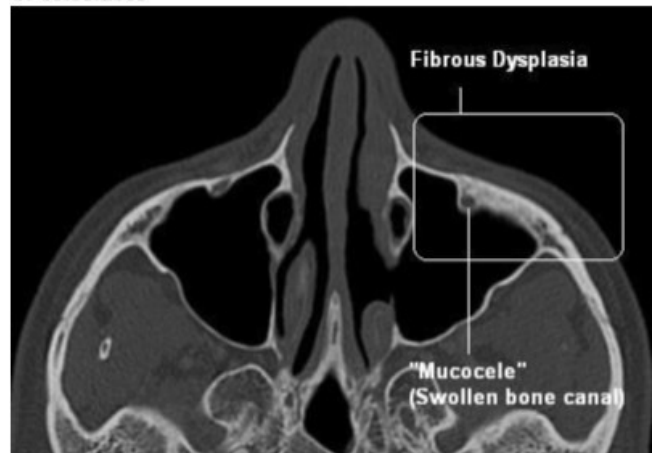


Before the third surgery

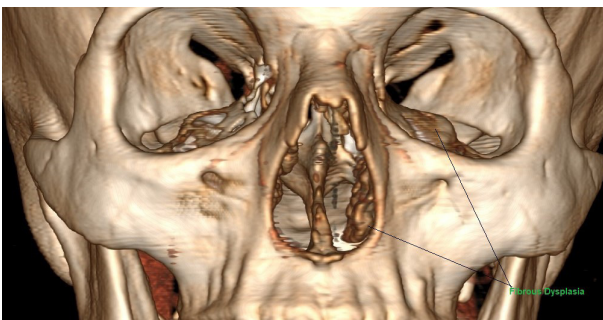CT 05.03.2009



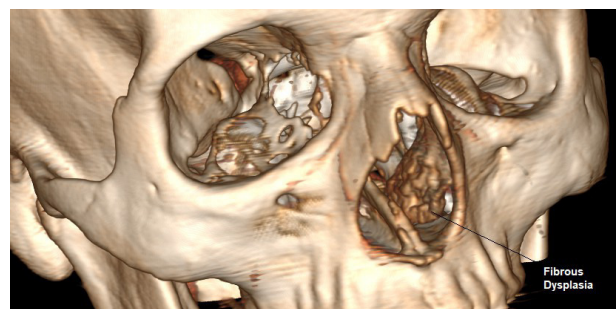
CT 05.03.2009



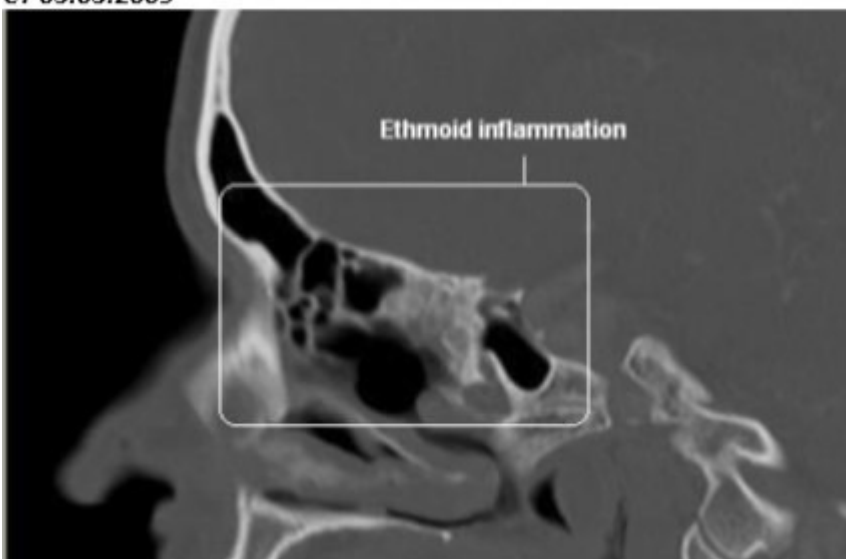
CT vom 05.03.2009



CT vom 05.03.2009

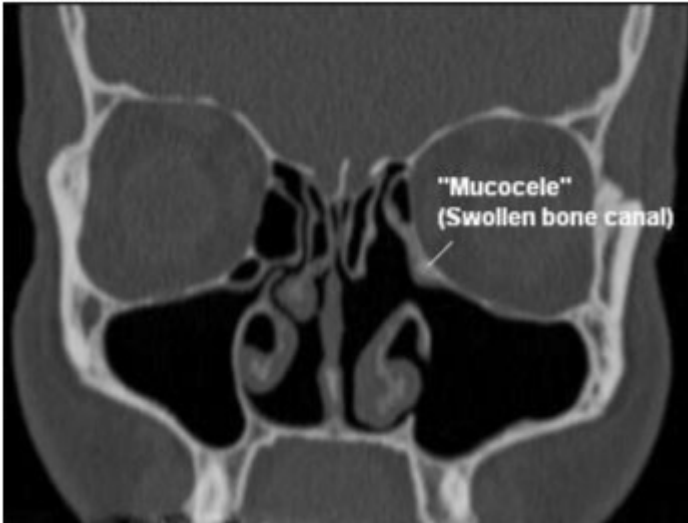


CT 05.03.2009

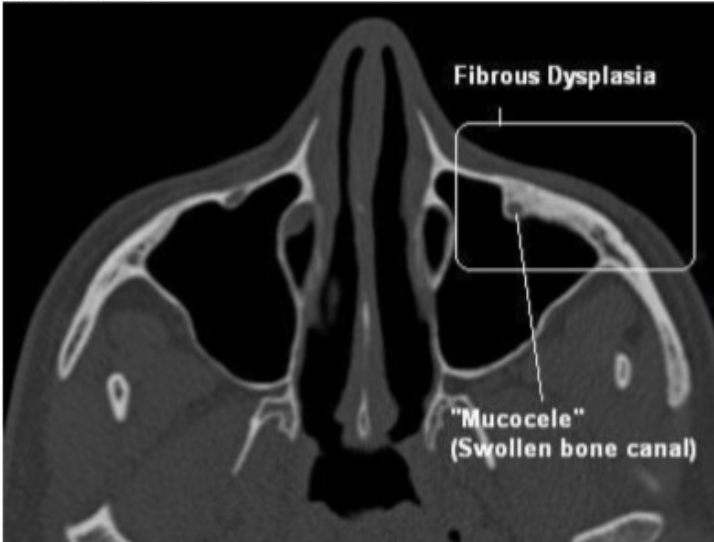


After the third surgery

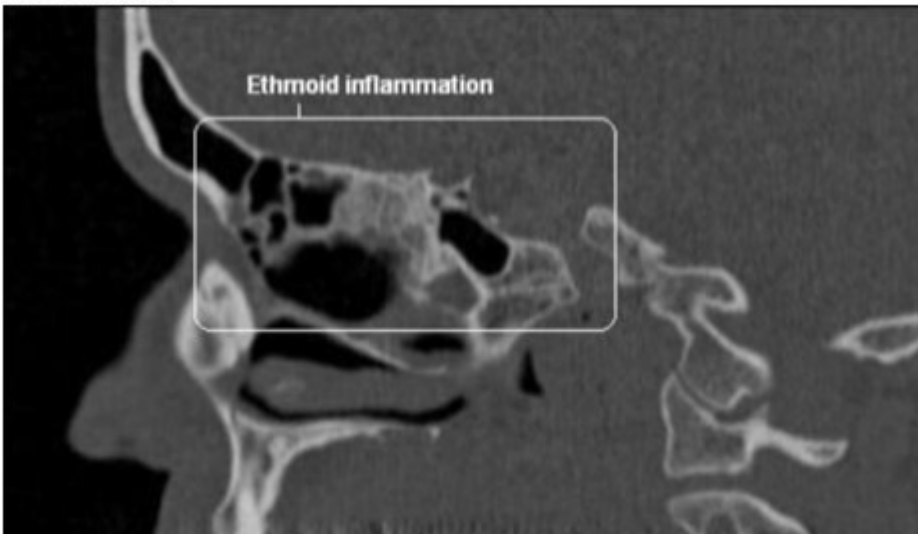
CT 17.12.2009



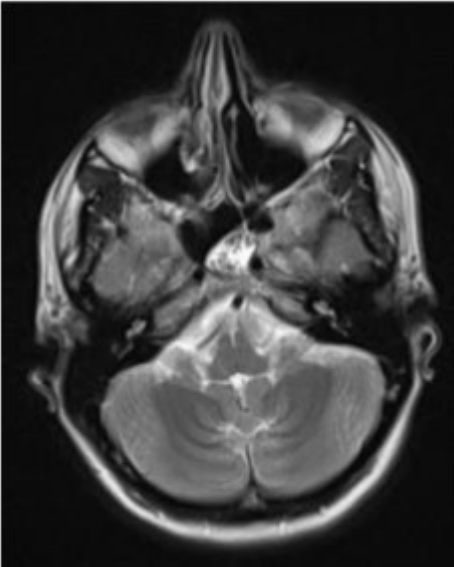
CT 17.12.2009



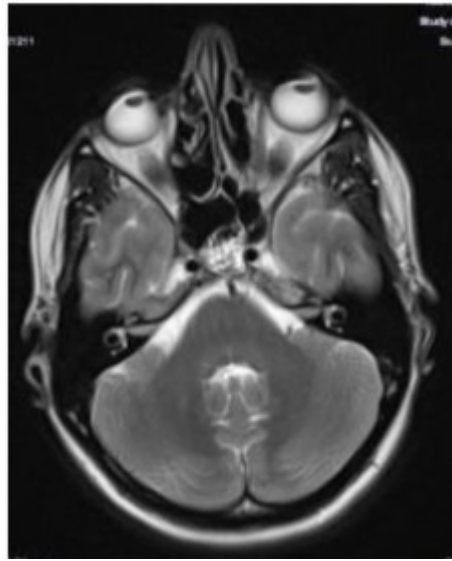
CT 17.12.2009



MRI vom 19.11.2009

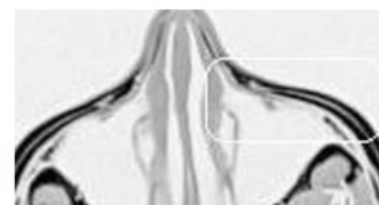
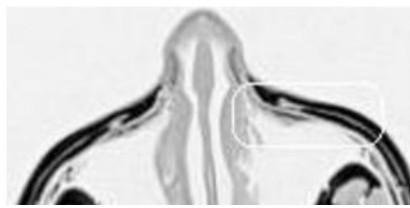
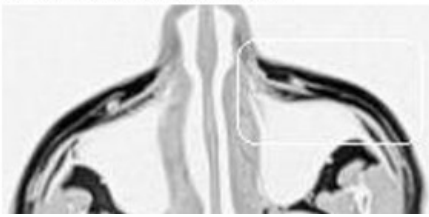


MRI vom 19.11.2009



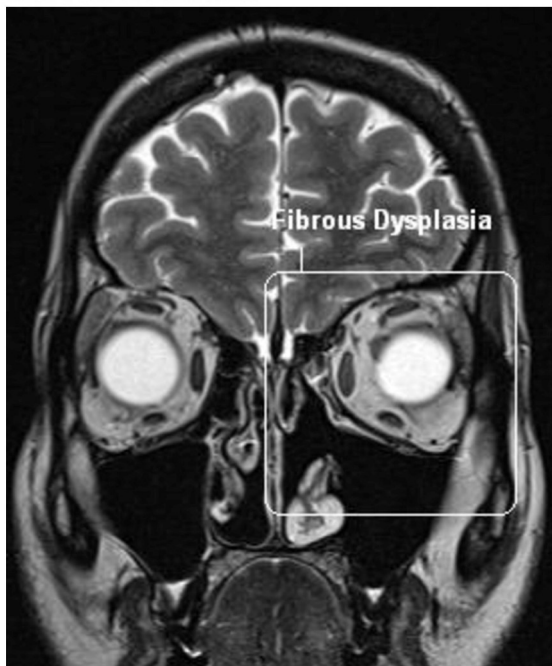
(Pinched trigeminal nerve)

MRI vom 19.11.2009

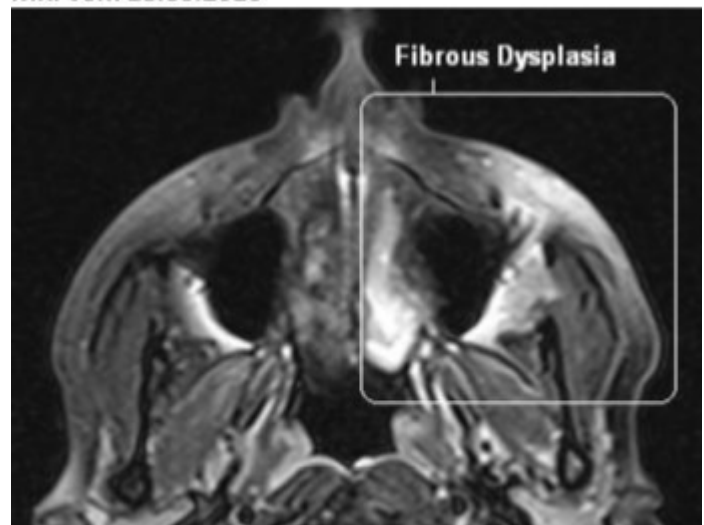


2010

MRI vom 18.03.2010

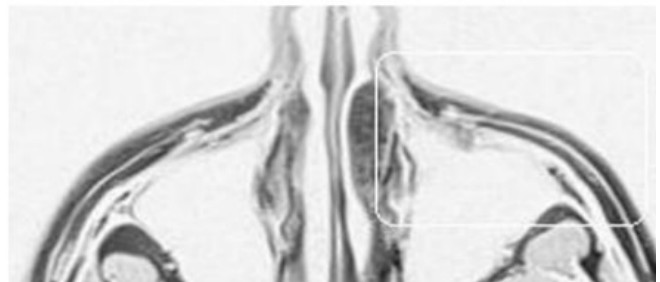
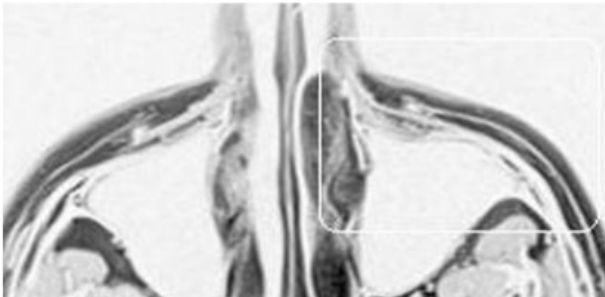
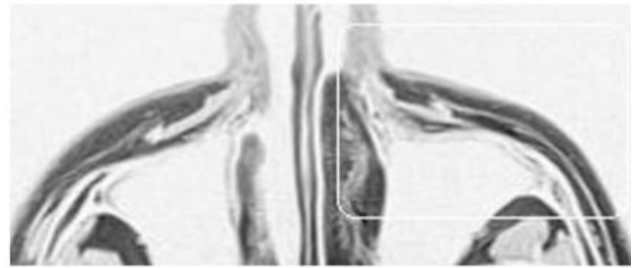
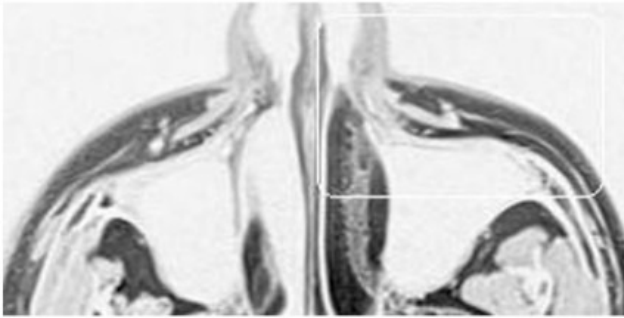


MRI vom 18.03.2010



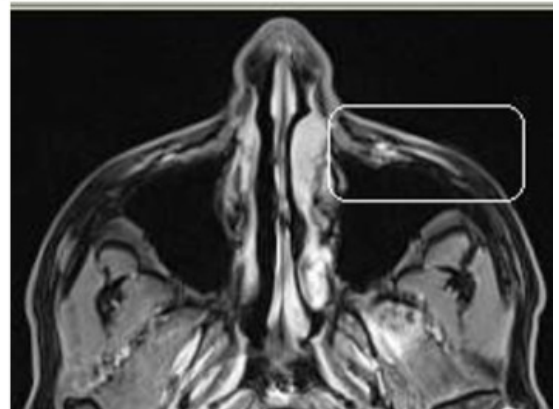
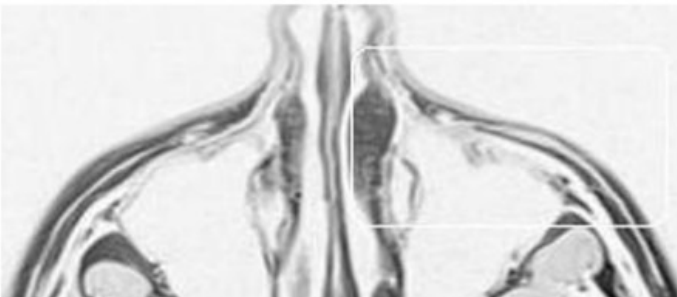
(Pinched trigeminal nerve)

MRI vom 18.03.2010



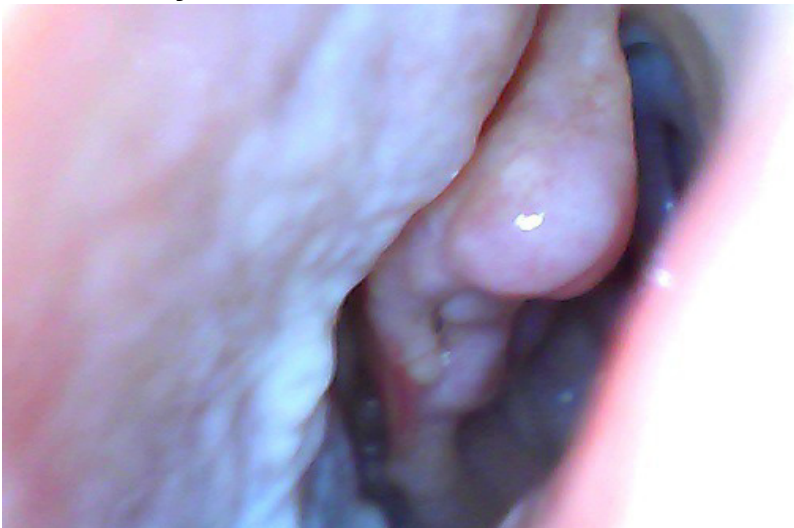MRI vom 18.03.2010

MRI vom 18.03.2010

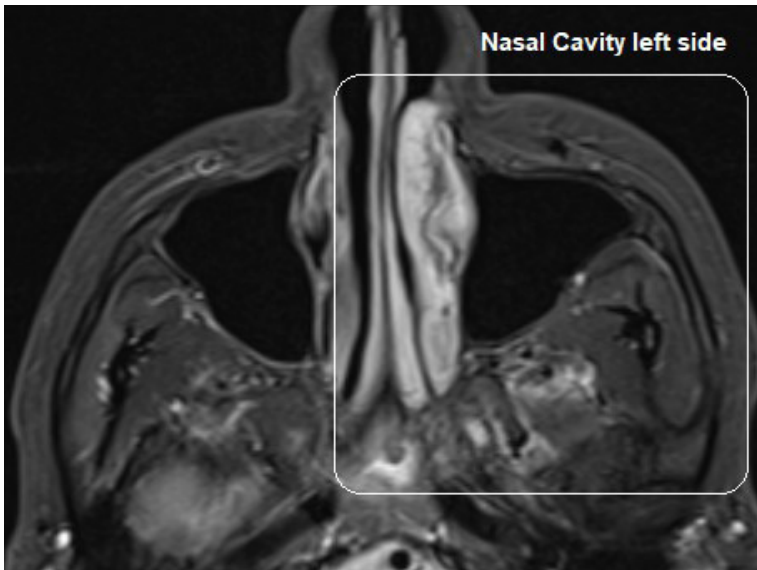


2018

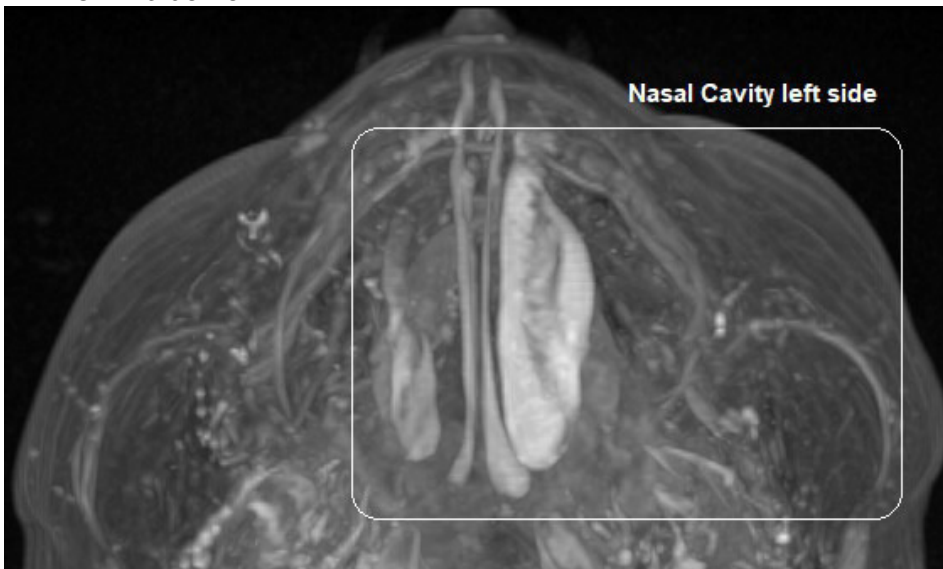Nasal Cavity left side (Polyp, strong infection because of the untreated Ethmoid inflammation)



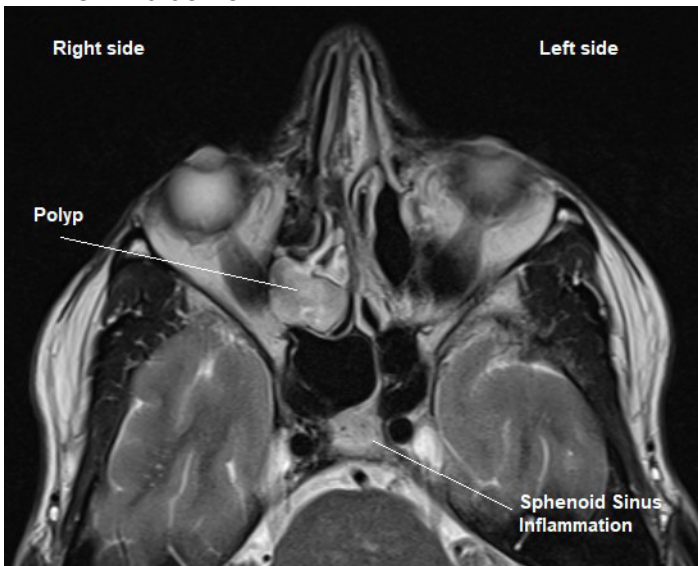
MR vom 16.08.18



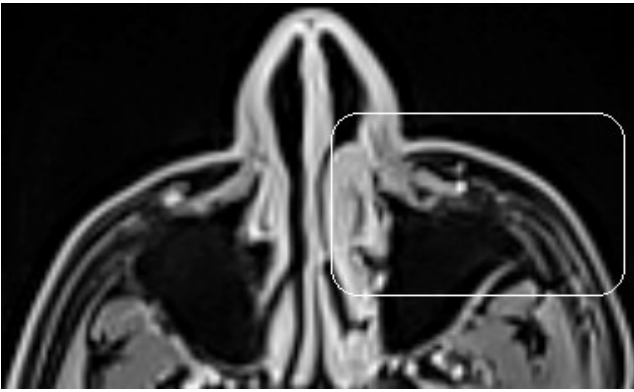
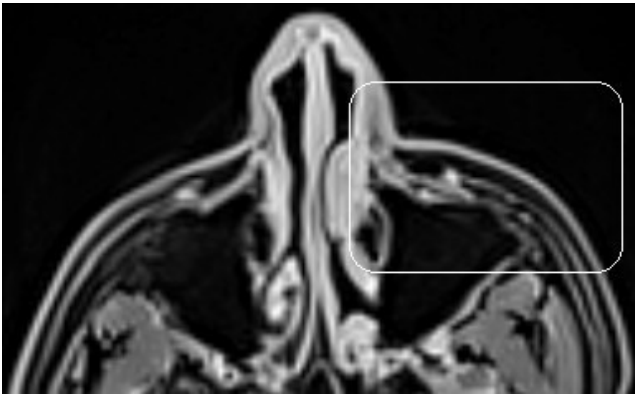
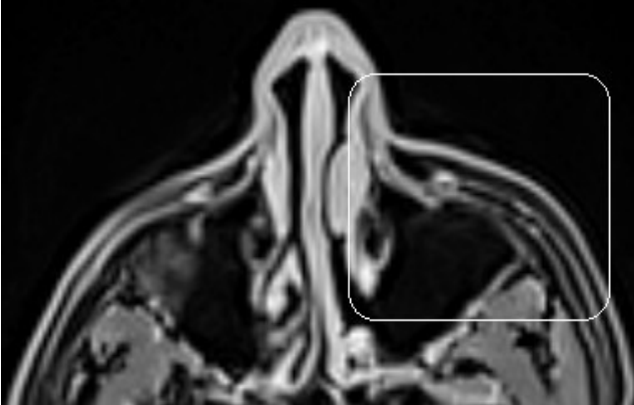
MR vom 16.08.18



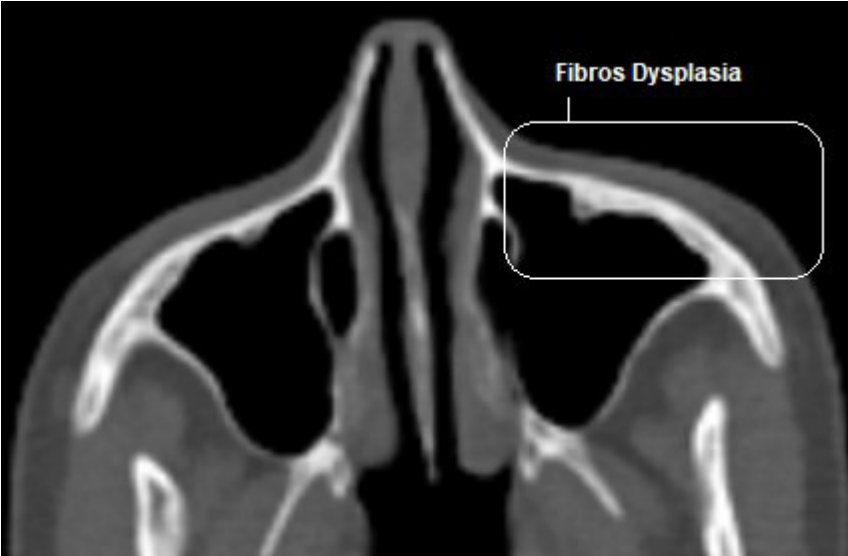
MR vom 16.08.18



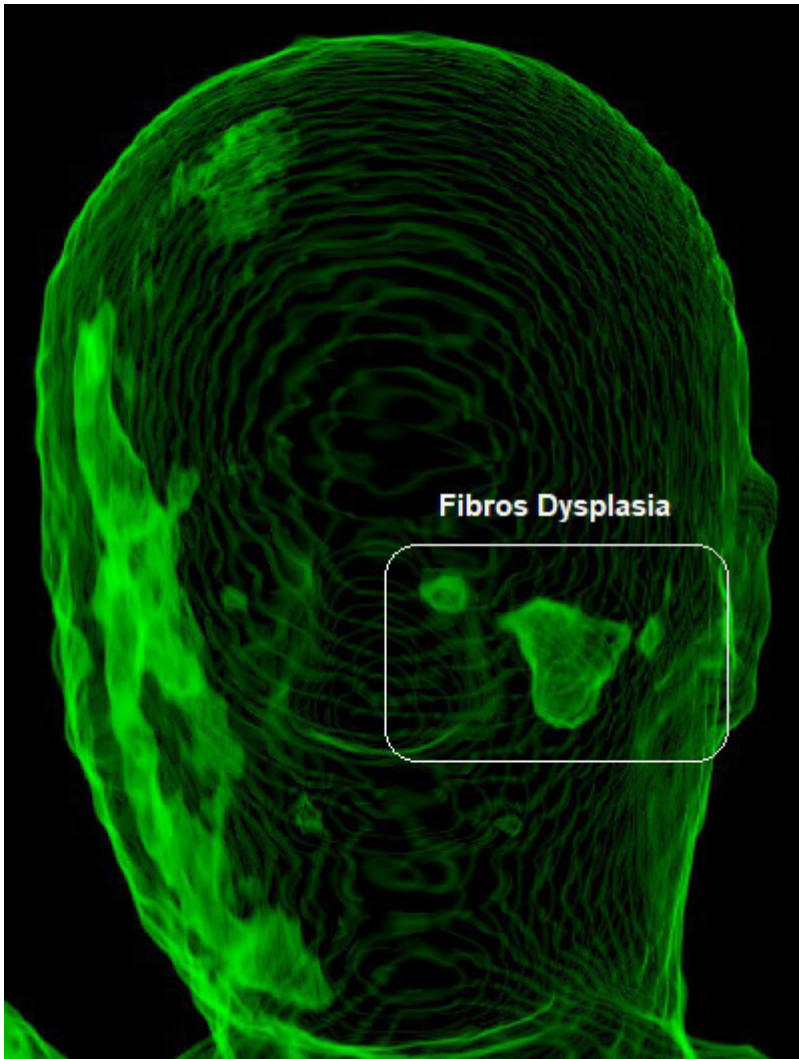
(Pinched trigeminal nerve)
MR vom 16.08.18



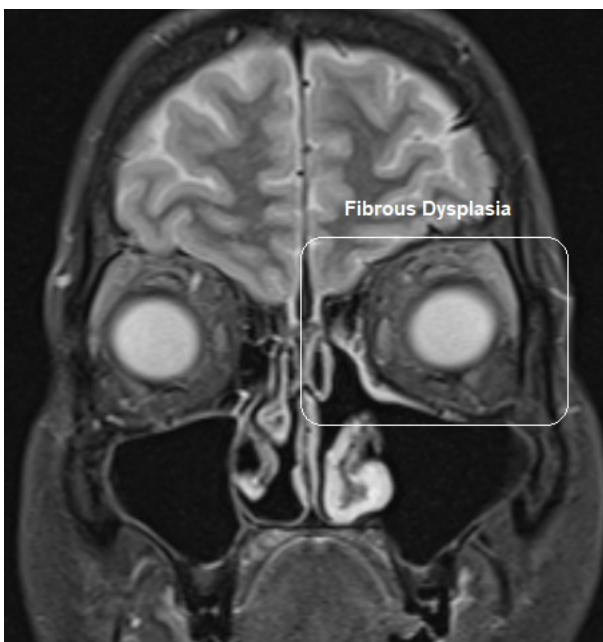
CT vom 14.03.18



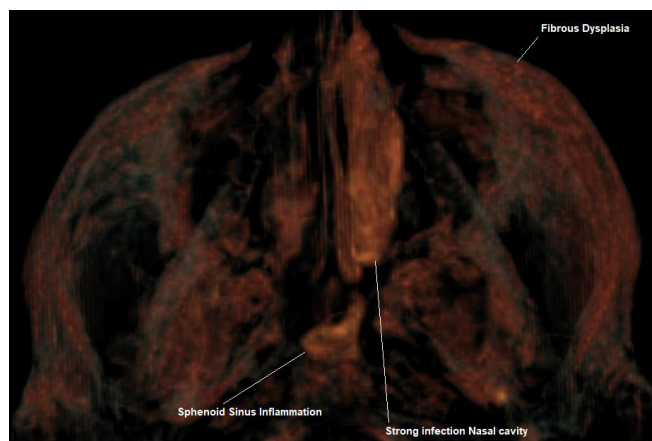
PET/CT vom 14.03.18



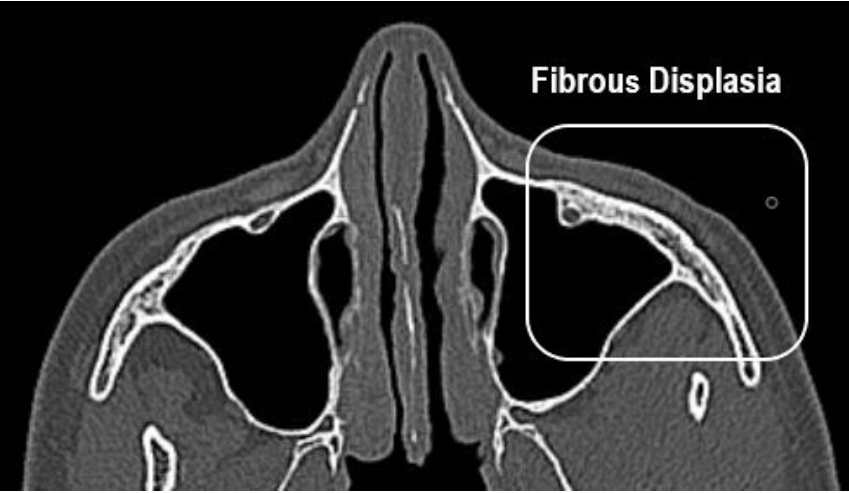
MR vom 16.08.18



MR vom 16.08.18



2023



After two weeks Antibiotics (Nasal Cavity left side, strong infection)

